12

Current Management of Posterior Wall Fractures of the Acetabulum

Berton R. Moed, MD
Philip J. Kregor, MD
Mark C. Reilly, MD
Michael D. Stover, MD
Mark S. Vrahas, MD

Abstract

The general goals for treating an acetabular fracture are to restore congruity and stability of the hip joint. These goals are no different from those for the subset of fractures of the posterior wall. Nevertheless, posterior wall fractures present unique problems compared with other types of acetabular fractures. Successful treatment of these fractures depends on a multitude of factors. The physician must understand their distinctive radiologic features, in conjunction with patient factors, to determine the appropriate treatment. By knowing the important points of posterior surgical approaches to the hip, particularly the posterior wall, specific techniques can be used for fracture reduction and fixation in these often challenging fractures. In addition, it is important to develop a complete grasp of potential complications and their treatment. The evaluation and treatment protocols initially developed by Letournel and Judet continue to be important; however, the surgeon also should be aware of new information published and presented in the past decade.

Instr Course Lect 2015;64:139–159.

An acetabular fracture routinely requires surgical intervention. The literature from the 1950s and 1960s offered conflicting recommendations for both nonsurgical and surgical treatment regimens.[1,2] It was agreed, however, that regardless of the treatment, the results after a hip injury would be poor if there was residual joint instability or incongruity between the femoral head and the weight-bearing area of the acetabulum.[1-4] In subsequent decades, evaluation and treatment protocols, which are still considered optimal, were developed and refined by Letournel and Judet[5] and published in their definitive 1993 text. New information and emerging trends have appeared in other book and journal articles, including *Instructional Course Lectures*.[6,7] However, these publications have focused primarily on the entire spectrum of acetabular fractures, with limited discussion of posterior wall fracture treatment. Posterior wall fractures are the most common type, accounting for approximately 25% of all acetabular fractures, and are often treated at community medical facilities.[5] With these facts in mind, it is important to refocus on this common—but potentially debilitating—injury by

Dr. Moed or an immediate family member has received royalties from Biomet and serves as a board member, owner, officer, or committee member of AO North America and the AO Foundation. Dr. Kregor or an immediate family member is a member of a speakers' bureau or has made paid presentations on behalf of Medtronic. Dr. Reilly or an immediate family member is a member of a speakers' bureau or has made paid presentations on behalf of Stryker. Dr. Vrahas or an immediate family member serves as a board member, owner, officer, or committee member of the AO Foundation. Neither Dr. Stover nor any immediate family member has received anything of value from or has stock or stock options held in a commercial company or institution related directly or indirectly to the subject of this chapter.

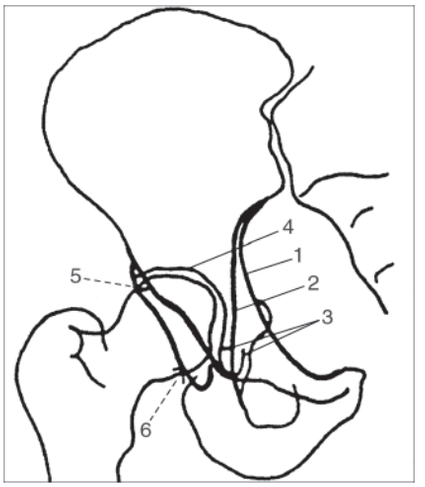

Figure 1 Schematic diagram showing the six acetabular landmarks seen on an AP radiograph: (1) iliopectineal line, (2) ilioischial line, (3) U or teardrop, (4) roof, (5) anterior rim, and (6) posterior rim. (Reproduced from Templeman D, Olson S, Moed BR, Duwelius P, Matta JM: Surgical treatment of acetabular fractures. *Instr Course Lect* 1999;48:481-496.)

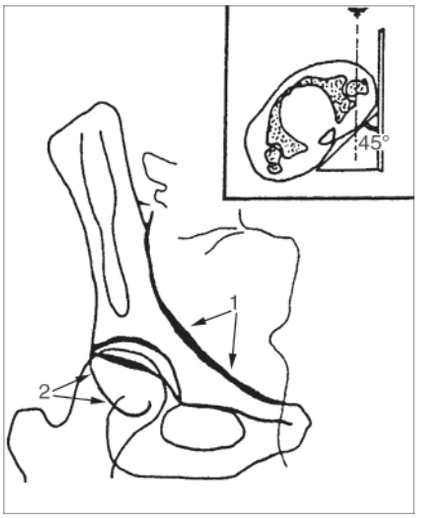

Figure 2 Schematic diagram showing the iliopectineal line (1) and the posterior rim (2) as seen on an obturator oblique radiograph. The obturator ring is seen en face. The proper amount of rotation for the obturator oblique view (inset) is present when the tip of the coccyx lies just above the center of the ipsilateral femoral head. (Adapted from Templeman D, Olson S, Moed BR, Duwelius P, Matta JM: Surgical treatment of acetabular fractures. *Instr Course Lect* 1999;48:481-496.)

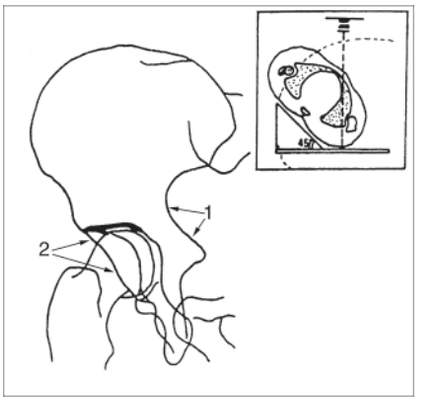

Figure 3 Schematic diagram showing the posterior border of the innominate bone (1) and anterior rim of the acetabulum (2) as seen on an iliac oblique radiograph. The iliac wing is seen en face. The anterior rim of the acetabulum can best be seen with this view. The proper amount of rotation for the iliac oblique view (inset) is present when the tip of the coccyx lies just above the center of the contralateral femoral head. (Adapted from Templeman D, Olson S, Moed BR, Duwelius P, Matta JM: Surgical treatment of acetabular fractures. *Instr Course Lect* 1999;48:481-496.)

reviewing the unique fracture radiology, surgical indications and techniques, pitfalls, and complications of posterior wall fractures.

Radiology of the Acetabulum and Posterior Wall Fracture Classification

The plane of the ilium is approximately 90° to the plane of the obturator foramen, and both structures are oriented approximately 45° to the frontal plane. On this basis, Judet et al[8] proposed that the AP view and two 45° oblique views of the pelvis can be used to study the radiographic anatomy of the acetabulum. Thus, the first systematic classification of acetabular fractures based on the anatomic pattern was derived, which later incorporated the analysis of two-dimensional CT scans.[5] Although three-dimensional CT technology has progressed, the diagnosis and the classification of posterior wall fractures, as with all acetabulum fractures, continues to be determined primarily by analyzing the aforementioned plain radiographic projections and two-dimensional CT scans (**Figures 1**, **2**, **3**, and **4**).

On the AP view, the rim of the posterior wall approximates a straight line and is more vertical than the anterior wall (**Figure 5**). Any break or deficit in this line indicates fracture or displacement of the posterior rim of the acetabulum. The signs of hip dislocation on the AP view include a break in the Shenton line, proximal migration of the lesser trochanter, relatively smaller size of the affected femoral head (closest to the x-ray cassette), and a bony double

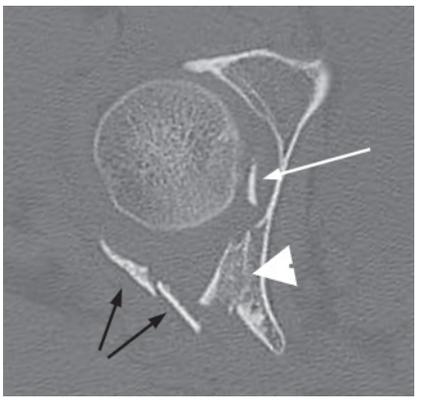

Figure 4 Axial CT scan showing a section through the acetabulum in which the posterior wall is fractured (black arrows) with marginal impaction (white arrowhead). An intra-articular loose body appears between the femoral head and the acetabulum (white arrow). (Copyright Berton R. Moed, MD, St. Louis, MO.)

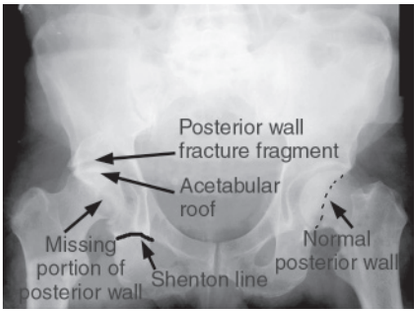

Figure 5 AP radiograph showing a dislocated right hip and a posterior wall fracture. (Copyright Berton R. Moed, MD, St. Louis, MO.)

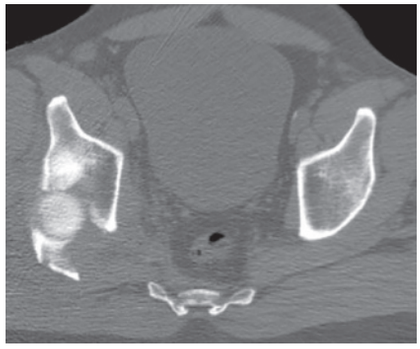

Figure 6 Two-dimensional CT section of the hip of the patient in Figure 5. (Copyright Berton R. Moed, MD, St. Louis, MO.)

Table 1
Additional Information Provided by a CT Scan

Intra-articular bony fragments
Intra-articular osteochondral fragments
Size of the posterior wall fracture
Location of the posterior wall fracture
Number of posterior wall fragments
Rotation of the fracture fragments
Marginal impaction of the articular surface
Fractures of the femoral head

density above the femoral head. The double density (**Figure 5**) is the posterior wall fragment. It often sits atop the dislocated femoral head and can give the appearance of normal joint space, potentially resulting in a misdiagnosis.

The obturator oblique view is especially helpful in diagnosing a posterior wall fracture because it places the posterior wall almost perpendicular to the x-ray beam and minimizes overlay of the anterior wall (**Figure 2**, inset). A dislocated hip will become more obvious on the obturator oblique view.[9] The iliac oblique view does not provide additional information specific to the posterior wall—other than showing the posterior border of the innominate bone (greater and lesser sciatic notch), which may be involved in an extended fracture. The CT scan provides additional information specific to posterior wall fractures that is not readily apparent on plain radiographs (**Table 1**). The contiguous sections should have a slice thickness of no more than 3 mm to provide satisfactory evaluation of the posterior wall (**Figures 4** and **6**).

The classification of acetabular fractures is based on a method originally developed in the 1960s by Letournel and Judet,[5,8] which was later refined into a system consisting of 10 fracture types: 5 elementary types and 5 associated (or combined) types[5,8] (**Table 2**). The Orthopaedic Trauma Association (OTA) comprehensive fracture classification system uses a basic alphanumeric coding of the acetabular fracture classification developed by Letournel and Judet and offers no clinical advantage. However, the OTA system is often used to allow computerized categorization and subclassification of the fracture types.[10] The posterior wall fracture is codified in the OTA system as type 62-A1 and is separated into three basic subgroups: fractures with a single posterior fragment (type 62-A1.1), fractures with multiple fragments (type 62-A1.2), and fractures with osteochondral fragments that are impacted into the underlying cancellous bone medial to the primary fracture line (type 62-A1.3, the so-called marginal impaction; **Figure 7**). These subgroups are then further categorized (**Table 3**).

Table 2
Letournel and Judet Classification of Acetabular Fractures

Elementary Fracture Types	Associated Fracture Types
Posterior wall	Posterior column and posterior wall
Posterior column	Transverse and posterior wall
Anterior wall	T-shaped
Anterior column	Anterior column and posterior hemitransverse
Transverse	Both-column

A potential point of confusion in the OTA classification is the use of "fracture-dislocation" in the subgroup descriptions. It is well known that fractures of the posterior wall can occur without any history of dislocation of the hip joint.[11] Acetabular fractures encompass a broad spectrum of injuries that are artificially separated by the classification systems into specific types. As such, there are many transitional types. For example, the type originally classified as a posteroinferior posterior wall fracture, with its extension superiorly into the greater sciatic notch and inferiorly into the ischium[5] (**Figure 8**), behaves more like a fracture of the

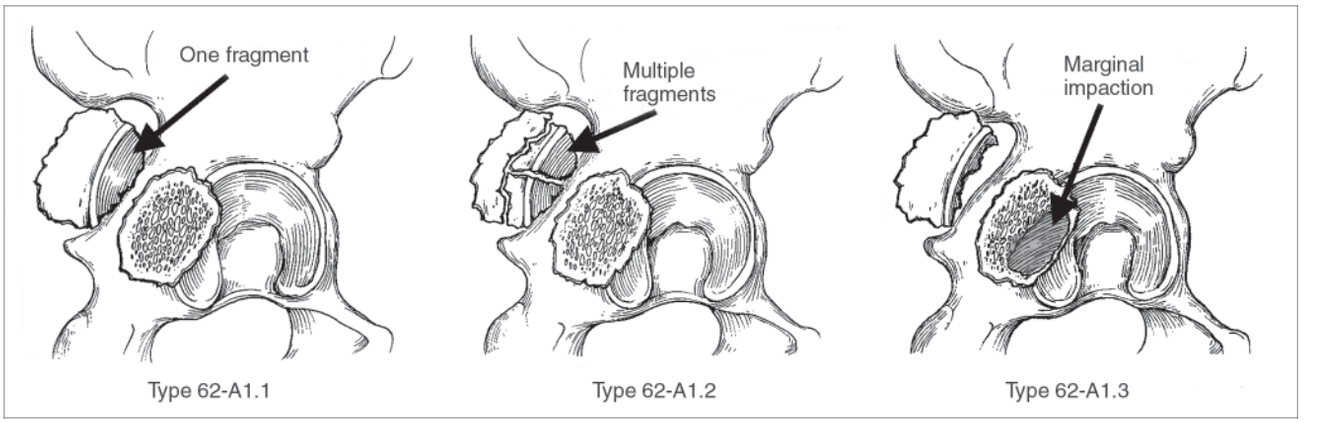

Figure 7 Orthopaedic Trauma Association classification showing the three subgroups of posterior wall fractures of the acetabulum. (Adapted from Baumgaertner MR: Fractures of the posterior wall of the acetabulum. *J Am Acad Orthop Surg* 1999;7:54-65.)

Table 3
Orthopaedic Trauma Association Classification of Posterior Wall Fractures

One Fragment (Type 62-A1.1)	Multifragmented (Type 62-A1.2, a*)	With Marginal Impaction (Type 62-A1.3, a*)
(1) Posterior	(1) Posterior	(1) Posterior
(2) Posterior superior	(2) Posterior superior	(2) Posterior superior
(3) Posterior inferior	(3) Posterior inferior	(3) Posterior inferior

The a* qualifiers are represented as follows: a^1 = one fragment; a^2 = two fragments; a^3 = more than two fragments.

Figure 8 Illustration of a fracture originally classified as a posteroinferior posterior wall fracture but now classified as a posterior column fracture. (Copyright Berton R. Moed, MD, St. Louis, MO.)

posterior column. It is now classified as a posterior column fracture.[10]

Preoperative Assessment and Indications for Surgery

Most patients who sustain isolated posterior wall fractures of the acetabulum are injured in motor vehicle crashes.[11,12] However, such fractures also can occur as the result of being struck by a motor vehicle or a fall from a height. Lower-energy mechanisms, such as sports-related trauma or simple falls, also can cause an acetabular fracture.[5,11] The injuring force is commonly applied axially through the femoral shaft, causing the femoral head to impact the posterior acetabular wall.[5] The position of the hip at the time of injury will determine the specific pattern of the acetabular fracture. Isolated fractures of the posterior wall occur with the hip in neutral to 25° of adduction.[5] The degree of hip flexion at the time of impact determines the level of the posterior wall fracture (for example, 90° for a posterior fracture, 60° for a posterosuperior fracture, and 115° for a posteroinferior fracture).[5] When the knee is flexed, the impact occurs at the knee, such as in a dashboard injury. When the knee is extended, the impact occurs at the foot. In a motor vehicle crash, the force is transmitted through the brake pedal or the floorboard. Because posterior wall fractures of the acetabulum usually result from high-energy blunt trauma, they are frequently associated with other musculoskeletal and visceral injuries. Therefore, it is important obtain a careful patient history and perform a complete physical examination.

Patients with posterior wall fractures of the acetabulum typically but not always present to the emergency department with hip pain. The surgeon,

therefore, must have a high level of suspicion for any lower extremity injury that potentially causes abnormal loading of the hip joint. Dislocation of the femoral head occurs in more than 85% of patients with a posterior wall fracture.[11] However, the absence of clinical signs of a dislocated hip or the lack of a history of hip dislocation does not preclude the presence of a substantial posterior wall fracture.[11,13] There should be shortening of the entire limb if the hip is dislocated. However, shortening of 1 to 2 cm is often difficult to determine in the clinical setting, and the physical findings regarding limb position commonly described for a pure posterior dislocation of the hip (flexion, adduction, and internal rotation of the hip with a shortened lower extremity) may not be present.

There are several reasons for this situation. First, posterior wall fractures can occur with or without an associated frank dislocation of the hip joint. In addition, the presence of a large posterior wall fracture allows the femoral head to dislocate directly posteriorly, without forcing the proximal femur into this abnormal position (**Figures 5** and **6**). A patient who initially sustains a posterior wall fracture-dislocation may have had the dislocation inadvertently reduced by emergency personnel on the scene while being stabilized for transport to the hospital. The patient who presents in the "classic" dislocated hip position probably will have either a relatively small posterior wall fracture fragment or a pure posterior dislocation. Normal limb positioning does not preclude the presence of a posterior wall fracture and actually may be associated with a large posterior wall fracture fragment.

Dislocation of the hip can be diagnosed on the initial AP radiograph (**Figure 5**). Prompt reduction is required because the rate of osteonecrosis increases dramatically if reduction is not performed within 12 hours of the dislocation.[11,13,14] With adequate sedation and pain medication, reduction often can be performed in the emergency department. Closed reduction in the operating room using general anesthesia is indicated after an initial failed attempt at closed reduction in the emergency department, when there are contraindications to the use of conscious sedation, or because of physician preference. Immediately after reduction, radiographs should be obtained to confirm a reduction of the dislocation. A postreduction CT scan is not universally required to confirm a concentric reduction; however, it provides valuable additional information and is generally recommended. A dislocated hip that cannot be reduced by closed means requires urgent open reduction and internal fixation (ORIF) of the posterior wall fracture.

All stable, concentrically reduced posterior wall fractures can be considered for nonsurgical management. With the hip stable and concentrically reduced, the presence of small intra-articular fragments, such as those residing in the acetabular fossa identified by CT, does not alter this situation. A history of hip dislocation is not necessarily an indication for surgical treatment.

CT-based measurements for posterior wall fracture size are not reliable predictors of a stable hip joint. Using the measurement method described by Moed et al,[14,15] a posterior wall fragment shown on a CT scan to involve 50% or more of the joint surface can be assumed to be unstable. However, any lesser involvement has little value for determining hip joint stability status because of the lack of sensitivity and specificity of these measurements.[15] Even experts in the field cannot make this determination using the patient history, plain radiographs, and CT scans.[16] Therefore, it is safest to assume that the hip is unstable unless proved otherwise. Dynamic fluoroscopic stress tests performed under general anesthesia (examination under anesthesia) should be used to select patients for nonsurgical treatment, as an alternative to surgical procedures on all posterior wall fractures of the acetabulum.[17] When it appears that the hip joint is congruent and should be stable, or stability is equivocal (such as with smaller posterior wall fractures), a dynamic stress examination should be performed to evaluate stability before deciding on nonsurgical management.[17]

An examination under anesthesia should be performed using the method described by Moed et al[14,15,17] in which the patient is placed supine with the hip in neutral rotation and full extension while under anesthesia. The hip is then slowly flexed past 90°, with progressive manual force applied through the hip along the longitudinal axis of the femur while the hip is visualized with C-arm image intensification. The applied force should be substantial, with the examiner using his or her entire body weight to axially load the hip through the femur. The examination is performed twice, using both AP and obturator oblique image intensifier projection. If the hip joint remains congruent during this assessment, the examination is repeated by adding about 20° of adduction and about 20° of internal rotation, which elicits instability more than flexion alone. Frank hip dislocation is neither required nor clinically desirable. Posterior subluxation demonstrated in either

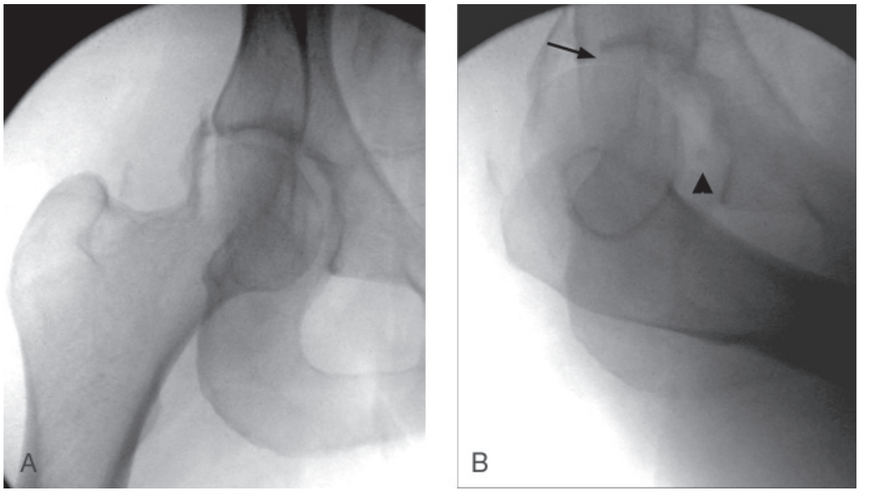

Figure 9 Image intensification views showing dynamic fluoroscopic examination under anesthesia in a patient with a small posterior wall fracture. **A,** The intraoperative obturator oblique view with the hip in neutral rotation and flexed to approximately 90° shows a located and congruent hip joint. **B,** The subsequent intraoperative obturator oblique view with the hip in neutral rotation and flexed to approximately 90° with axial load applied shows gross subluxation with loss of hip joint parallelism and joint congruency (arrow) and gross enlargement of the medial clear space (arrowhead). (Reproduced with permission from Moed BR, Ajibade DA, Israel H: Computed tomography as a predictor of hip stability status in posterior wall fractures of the acetabulum. *J Orthop Trauma* 2009;23:7-15.)

view (indicated by a widening medial joint space or a loss of joint parallelism) indicates dynamic hip instability (**Figure 9**).

In addition to joint instability, joint incongruity is an indication for surgical treatment. Joint incongruity is usually caused by intra-articular osteochondral fracture fragments interdigitated between the femoral head and the acetabular articular surface, which result in residual subluxation of the hip joint. Although usually obvious on plain radiographs, two-dimensional CT provides better visualization. When hip stability is in doubt, skeletal traction is recommended, pending further evaluation. Unstable hips often require skeletal traction after reduction. Preoperative skeletal traction will prevent recurrent dislocation, as well as femoral head articular wear from incarcerated intra-articular osteochondral fragments, while awaiting surgical treatment.

Commonly, acetabular fracture surgery is performed between 2 and 5 days after injury because of concern that an earlier surgical procedure would place patients at risk for increased blood loss. However, a recent study has shown that posterior wall fractures might be a subset of acetabular fractures that can be treated immediately without increased risk of excessive blood loss.[18] Indications for emergent surgery include a hip dislocation that is irreducible by closed means, a hip dislocation after reduction that is unstable with traction, a posterior wall fracture with an associated femoral neck fracture, and an open posterior wall fracture.

It is uncommon to select nonsurgical treatment for a patient with surgical indications. However, this option should be considered when there are medical contraindications to anesthesia or severe osteopenia exists that precludes stable internal fixation. Older patients with severely comminuted fractures may be better treated with total hip arthroplasty (THA).[11,13] In general, patients older than 55 years with more than three intra-articular fragments and marginal impaction should be considered as potential candidates for THA, rather than ORIF. However, the decision to proceed with THA is based on many factors and is a judgment call based on the surgeon's experience.

Surgical Approach Options

Most posterior wall fractures can be addressed with a standard Kocher-Langenbeck approach.[5] However, for a superior posterior wall fracture (**Figure 10**), modifications of this standard approach may be necessary for adequate visualization without surgical devitalization of the gluteus medius muscle and the superior gluteal neurovascular bundle. The modified approaches are the Kocher-Langenbeck approach with the Ganz trochanteric flip osteotomy and the modified Gibson approach.[19,20]

Standard Kocher-Langenbeck Approach

The standard Kocher-Langenbeck approach (**Figures 11** and **12**) may be performed with the patient either in a lateral position with a pelvic stabilizer and the leg draped free or in the prone position. The prone position may be used in combination with a specialized acetabular fracture table, which facilitates distraction of the hip joint and allows for hip flexion by control of a leg spar. A universal distractor is a useful alternative to a specialized table (**Figure 13**).

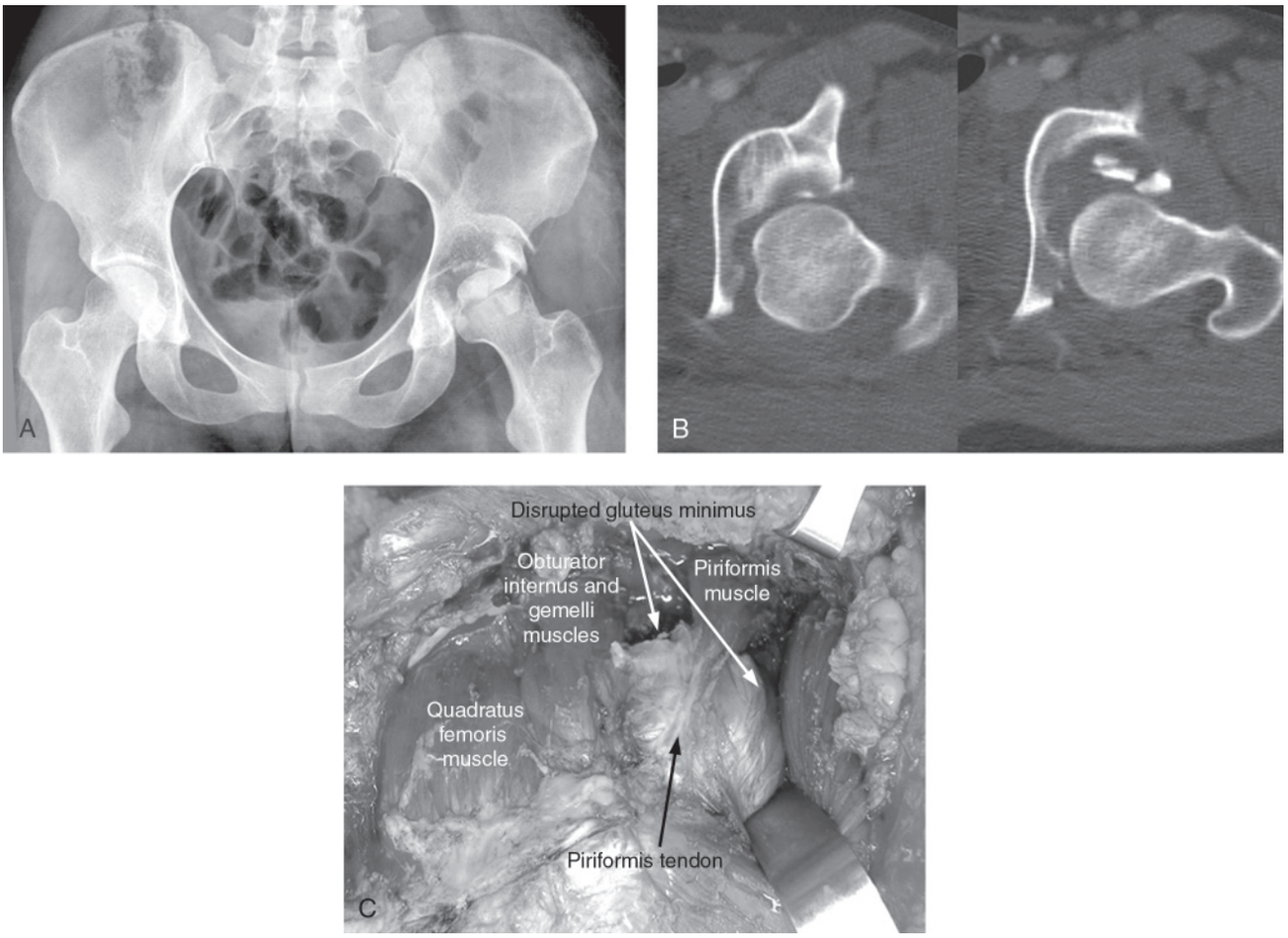

Figure 10 **A,** AP pelvic radiograph of a patient with a left superior extended posterior wall acetabular fracture showing involvement of the radiographic roof, indicating the superior nature of the fracture. **B,** Representative CT images from superior (left) to inferior (right) of the left extended posterior wall fracture showing extension nearly to the anterior inferior iliac spine. **C,** Intraoperative anatomy of the left superior wall acetabular fracture with the gluteus medius muscle retracted. For orientation, superior is on the right and lateral is on the bottom of the photograph. Note the disruption of the gluteus minimus muscle (white arrows), a portion of which underlies the piriformis tendon, caused by the displacement of the posterior wall fracture. Visualization and fixation of this fracture would be difficult with a standard Kocher-Langenbeck approach. A modified Gibson approach or a trochanteric flip osteotomy is advised. (Adapted with permission from Kregor PJ, Stover M: Acetabular fractures, in Stannard JP, Schmidt AH, Kregor PJ, eds: *Surgical Treatment of Orthopaedic Trauma*. New York, NY, Thieme, 2007, pp 471-521.)

A typical belief is that the Kocher-Langenbeck approach for a posterior wall fracture of the acetabulum is identical to that for THA. However, there are many critical differences. Maintenance of the blood supply from the ascending branch of the medial femoral circumflex artery is paramount in acetabular fracture surgery but is sacrificed in THA.[21] In addition, the normal anatomy of the gluteus minimus and the short external rotators is usually distorted by a posterior wall fracture. Furthermore, joint capsule integrity must be maintained because it is usually the sole surviving soft-tissue attachment to the posterior wall fragment, yet it is sometimes sacrificed in THA. The sciatic nerve is identified and protected during posterior wall acetabular fracture surgery, whereas it is avoided and left undisturbed during THA.

As in all surgical approaches, a regimented and logical sequence for the Kocher-Langenbeck approach should be followed to prepare for fixation of a posterior wall fracture of the acetabulum. The steps of the approach are as follows: (1) The skin incision begins proximally, approximately 5 cm from the posterior iliac crest, and has an apex at the greater trochanter. The distal incision continues approximately 15 to

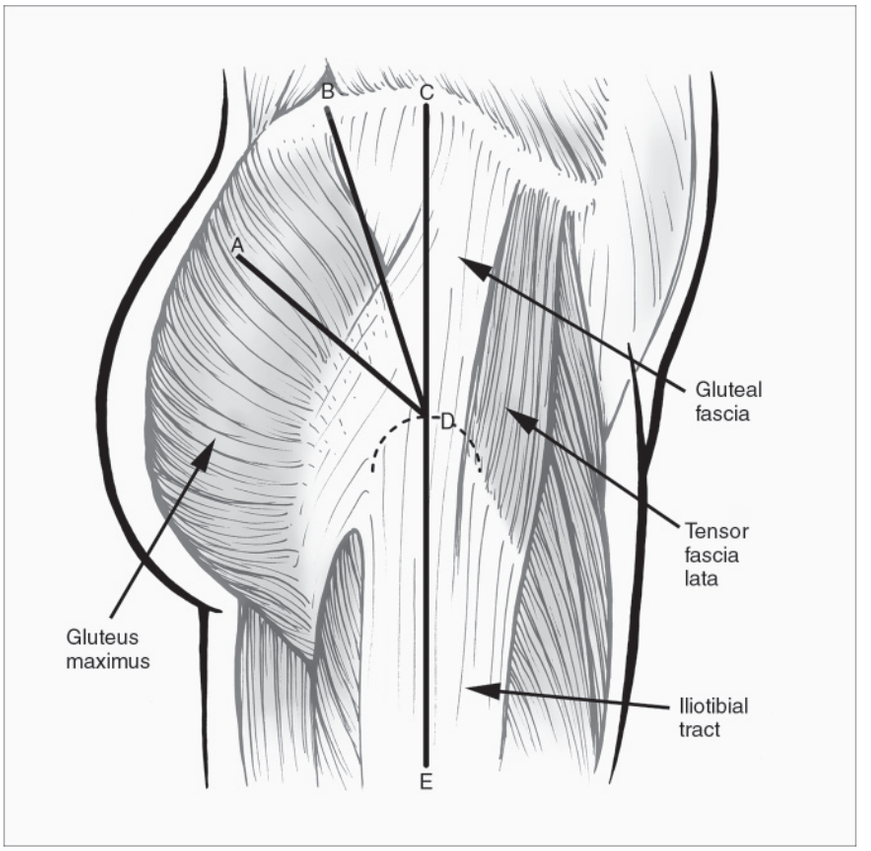

Figure 11 Kocher-Langenbeck and modified Gibson incisions. The greater trochanter is outlined by black dashes (D). Angle ADE shows the location of the Kocher-Langenbeck skin incision superimposed on the gluteal fascia. Angle BDE shows the location of Gibson's original skin incision superimposed on the gluteal fascia. The straight line (CDE) shows the current skin incision for the modified Gibson approach. (Copyright Berton R. Moed, MD, St. Louis, MO.)

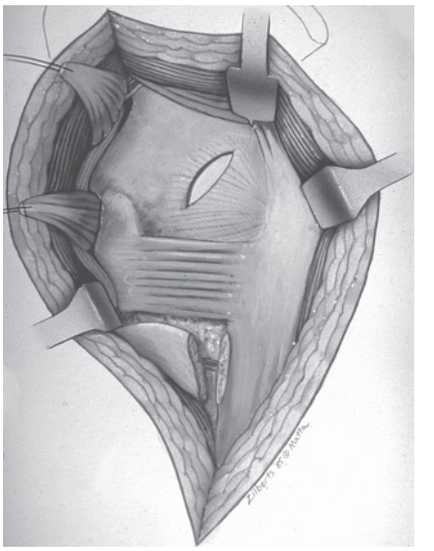

Figure 12 Illustration showing the Kocher-Langenbeck approach final exposure of the retroacetabular surface. (Adapted from Matta JM, Letournel E, Browner BD: Surgical management of acetabular fractures. *Instr Course Lect* 1986;35:382-397.)

20 cm along the midlateral aspect of the femur. (2) Skin flaps should not be created between the subcutaneous fat and the fascia. (3) The iliotibial band is incised distally and split up to the level of the greater trochanter. A common mistake is to make this incision too posterior, because this would misalign the subsequent split in the gluteus maximus and limit the anterior extent of the surgical exposure. In addition, it is important to ensure it is not too close to the insertion of the gluteus maximus. (4) The gluteus maximus is split between the anterosuperior one-third and the posteroinferior two-thirds in line with the muscle fibers. (5) The gluteus maximus is released 1.0 to 1.5 cm from its insertion on the posterolateral border of the femur. Deep to this tendon, approximately 1.0 to 1.5 cm from the cephalad border, is a branch of the first perforator. Anticipation and coagulation of this vessel will minimize blood loss during tendon release. Although the tendon of the gluteus maximus does not need to be released in all cases, release does allow better posterior flap mobilization. (6) The sciatic nerve should be visualized on the posterior surface of the quadratus femoris (**Figure 14**) and protected through the remainder of the surgical procedure. (7) The interval between the quadratus femoris and the obturator internus should be developed, with its attached superior and inferior gemelli muscles (also known as the triceps coxae muscle). The quadratus femoris should be maintained because it protects the blood supply of the femoral head. (8) The obturator internus tendon and the piriformis tendon are released 1.5 cm from their attachments on the greater trochanter. Releasing the tendon too close to the greater trochanter will jeopardize the blood supply of the femoral head. (9) The interval between the capsule, the piriformis, and the obturator internus are developed while maintaining the integrity of the capsule. (10) The gluteus minimus is elevated off the posterior wall and the superior acetabular area. Any devitalized muscle is débrided. (11) A design-specific sciatic nerve retractor is placed with its

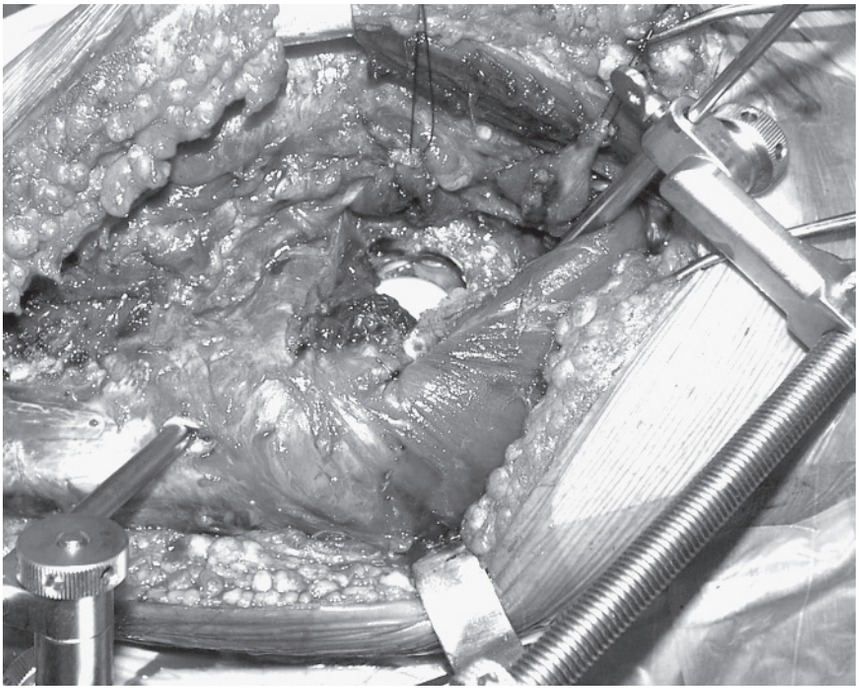

Figure 13 Intraoperative photograph of distraction of the hip joint with aid of the universal femoral distractor. One 6.0- or 5.0-mm Schanz screw is placed in the sciatic buttress, and another is placed in the proximal femur at the level of the lesser trochanter. For orientation, superior is on the right and lateral is on the bottom of the photograph. (Reproduced with permission from Kregor PJ, Stover M: Acetabular fractures, in Stannard JP, Schmidt AH, Kregor PJ, eds: *Surgical Treatment of Orthopaedic Trauma*. New York, NY, Thieme, 2007, pp 471-521.)

tip in the lesser sciatic notch, and the obturator internus muscle belly is used to cushion the nerve from the retractor. Care must be taken to ensure that the cephalad and caudal edges of the retractor (where the nerve is not cushioned) do not impinge on the nerve. (12) The fracture edges are débrided and may be aided by a small curet, a scalpel blade, and a suction tip.

After appropriate reduction and fixation of the posterior wall fracture, the wounds are irrigated, and the tendons of the gluteus maximus, the piriformis, and the obturator internus are repaired. After closure of the iliotibial band, the subcutaneous tissues and skin are closed.

Modified Gibson Approach

In the setting of an extended superior posterior wall fracture of the acetabulum that reaches beyond the 12-o'clock position anteriorly, visualization and reduction of the posterior wall fracture are limited by the gluteus medius muscle belly and the superior gluteal nerve and vessels. In this case, for added superior or anterior exposure, the modified Gibson approach as described by Moed[20] is beneficial. It relies on an interval anterior to the gluteus maximus, rather than through the muscle belly. In that regard, it also may be considered more muscle sparing. It also has the potential to provide otherwise equivalent inferior and posterior access while minimizing risk to the neurovascular supply to the anterior portion of the gluteus maximus muscle. However, exposure relative to the Kocher-Langenbeck approach may be limited for a fracture that requires access to the entire greater sciatic notch, which is unusual for fractures of the posterior wall.

Similar to the Kocher-Langenbeck approach, the modified Gibson approach may be performed with the patient positioned either prone or lateral. Moed[20] described a straight incision 20 to 30 cm midlateral on the thigh (**Figure 11**). It is important to know that the gluteus maximus muscle inserts onto the iliotibial band anterior to the anterior border of the greater trochanter in young, muscular patients. In elderly patients, this is more posterior. Branches of the inferior gluteal artery that perforate the fascia lata and continue to the subcutaneous tissue identify the anterior border of the gluteus maximus. The fascial cuff around the gluteus maximus is incised and maintained for later closure. The gluteus maximus is retracted in a posterolateral direction and aided by releasing the insertion of the gluteus maximus from the posterolateral aspect of the femur. Anterior retraction of the gluteus medius facilitates anterosuperior access of the posterior wall. Release of the piriformis and the obturator internus is the same as for the standard Kocher-Langenbeck approach.

Ganz Trochanteric Flip Osteotomy

The Ganz trochanteric flip osteotomy may have some limited use in extended posterior wall fractures, in posterior wall fractures associated with femoral head fractures (Pipkin type IV injuries), and when a surgical dislocation of the femoral head (and intra-articular visualization) is desired.[19] This surgical

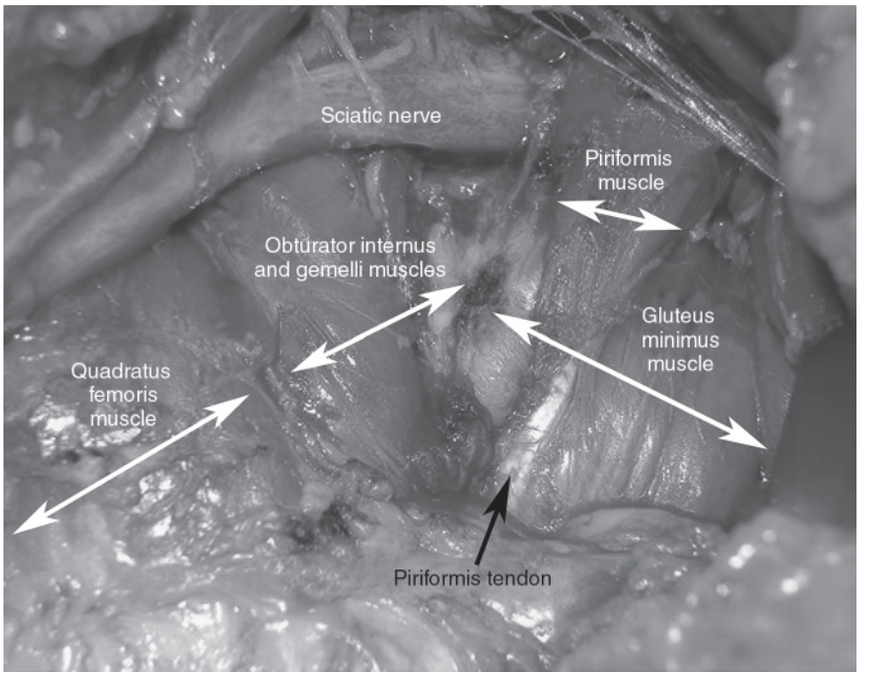

Figure 14 Intraoperative view of the relationship of the sciatic nerve to the quadratus femoris muscle, the obturator internus with attached superior and inferior gemelli muscles (also known as the triceps coxae muscle), and the piriformis muscle. For orientation, superior is on the right and lateral is on the bottom of the photograph. The sciatic nerve is best found on the posterior border of the quadratus femoris muscle. It runs posterior to the conjoint tendon and in most cases anterior to the piriformis muscle belly. (Reproduced with permission from Kregor PJ, Stover M: Acetabular fractures, in Stannard JP, Schmidt AH, Kregor PJ, eds: *Surgical Treatment of Orthopaedic Trauma*. New York, NY, Thieme, 2007, pp 471-521.)

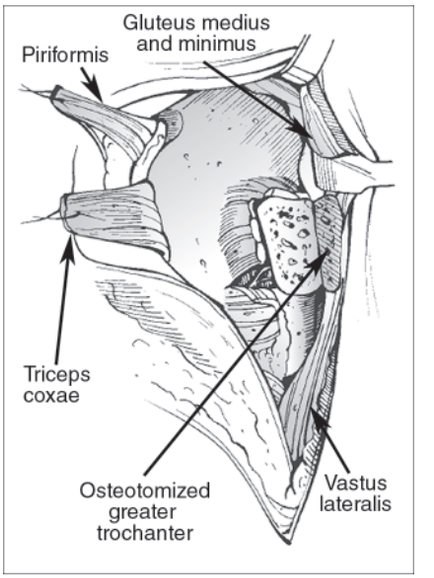

Figure 15 The trochanteric flip osteotomy using a Kocher-Langenbeck approach. Exposure of the supra-acetabular area after anterior retraction of the osteotomized trochanter showing the trigastric attachments of the gluteus medius and minimus muscles attached proximally and the vastus lateralis muscle attached distally. (Adapted with permission from Moed BR, Reilly M: Fractures of the acetabulum, in JD Heckman et al, eds: *Rockwood and Green's Fractures in Adults*, ed 7. Philadelphia, PA, Lippincott Williams & Wilkins, 2009, pp 1463-1523.)

approach is performed with the patient in the lateral position with the ipsilateral leg draped free. Classically, the gluteus maximus is split as in the Kocher-Langenbeck approach, but it also may be performed using the modified Gibson interval (anterior to the muscle belly of the gluteus maximus). The insertions of the piriformis and the obturator internus are left intact before osteotomizing the greater trochanter to protect the ascending branch of the medial femoral circumflex artery. The vastus lateralis is elevated proximally in the area of the vastus lateralis ridge. The major component of the approach is based on a 1.5-cm thick osteotomy of the greater trochanter (made superficial to the tendon insertions of the piriformis and the obturator internus) with the gluteus medius and minimus muscles attached proximally and the vastus lateralis muscle attached distally (**Figure 15**). The piriformis tendon and the obturator internus tendon (with its attached superior and inferior gemelli muscles) may then be released 1.5 cm from their insertions. A key to the approach is the posterior-to-anterior sharp elevation of the gluteus minimus from the supra-acetabular region of the ilium. The leg can then be flexed, adducted, and externally rotated to allow access to the anterior inferior iliac spine. Therefore, without surgical dislocation of the femoral head, excellent exposure can be obtained for posterior wall fractures. In some cases, it may be desirable to make a Z incision in the hip capsule to allow surgical dislocation of the femoral head. When this capsulotomy is performed, it is important to maintain the capsular attachments to the posterior wall fracture fragments, thereby maintaining their blood supply. Dislocation of the femoral head then can be accomplished by a combination of hip flexion, adduction, and external rotation. In this way, intra-articular visualization or treatment of an associated femoral head fracture can be facilitated.

Surgical Reduction and Fixation Methods

As discussed previously, the patient can be positioned either prone or lateral on an orthopaedic fracture table or a standard radiolucent operating table. Regardless of the patient position or the operating table used, it is important that adequate intraoperative fluoroscopic imaging of the acetabulum can be obtained during the surgical procedure. The C-arm image intensifier used for intraoperative fluoroscopic imaging is placed on the side opposite the primary surgeon. The hip should remain extended and the knee flexed throughout the procedure to reduce tension and risk of injury to the sciatic nerve. If hip flexion is required to gain intra-articular access for loose body removal and joint débridement, this position should be maintained for very short periods (less than 5 or 10 minutes). In the prone position, a femoral transcondylar pin attached to the fracture table facilitates control of hip and knee position, as well as traction force, to minimize iatrogenic sciatic nerve injury. With the patient lateral, the surgeon must remain attentive to the position of the leg throughout the procedure.

After the surgical approach is completed, exposing the posterior wall and column, the posterior wall fracture fragments then must be carefully delineated and cleared of debris. The surgeon must be cognizant of the capsular blood supply to the articular fragments. Limiting periosteal elevation to the fracture site as much as possible helps avoid further devascularization. Under no circumstances should any wall fragment containing articular cartilage be released from its capsular attachment. Rotating the fragments on their capsulolabral attachments will allow visualization and débridement of these fragments with their articular surface and the hip joint itself. The subsequent removal of free osteochondral fragments and débridement of the hip joint is accomplished by distracting the femoral head (**Figure 13**), which can be accomplished by using traction applied from the fracture table, from a universal distractor, or manually with a Schanz screw temporarily placed into the proximal femur.

The retrieval of large osteochondral fragments may be difficult. Often, sufficient hip joint access for this purpose can be obtained by time-limited positioning of the hip in flexion (with the knee still flexed) combined with strong in-line traction. Infrequently, temporary hip joint redislocation may be needed. Hip joint redislocation can provide increased digital or instrument access. Unfortunately, direct visual access is often impaired. The number and the size of intra-articular fragments determined preoperatively from the CT scan are used to ensure adequate removal. As they are removed, the position and the orientation of the free osteochondral fragments should be noted. This information will help the surgeon in the later repositioning of each fragment. The ligamentum teres is sharply débrided from the cotyloid fossa, and the joint is thoroughly irrigated to ensure that all debris has been removed. Otherwise, the torn ligamentum teres may become interposed between the femoral head and the intact acetabulum. The resulting incongruency can adversely affect the subsequent reduction of the posterior wall fragments. If a fragment of the posterior wall is incarcerated in the joint with intact capsular attachments, these attachments should not be sacrificed to retrieve the fragment. The capsular hinge is usually at the anterior aspect of the wall fragment. Usually, a long right-angle clamp can be advanced anteriorly to the point of the capsular attachment, and the retained wall fragment then can be teased from the joint. If this maneuver is unsuccessful, a trochanteric flip osteotomy may be needed to safely access this fragment to extract it from the joint with its capsular attachments intact.

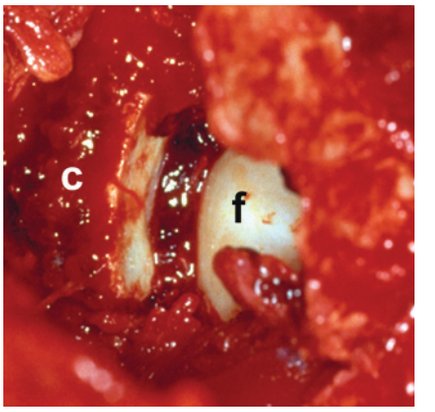

Figure 16 Intraoperative photograph showing the femoral head (f) and an impacted and slightly comminuted articular surface with the underlying compressed cancellous bone (c). (Copyright Berton R. Moed, MD, St. Louis, MO.)

The reduction of the femoral head into the intact anterior acetabulum is then visually and fluoroscopically verified. After the position of the femoral head is determined to be correct, the femoral head is used as a template for reducing the free osteochondral articular fragments and marginal impaction (**Figure 16**). Impacted fragments should be mobilized with underlying cancellous bone, reduced against the head, and held provisionally in place. Free osteochondral fragments are likewise reduced against the head and held provisionally in place. Any remaining underlying bony defect is filled with

structural graft. Bone graft is most often easily obtained from a window in the greater trochanter, but synthetic bone-void fillers or cancellous allograft also may be used for this purpose.[5,11,22] Although the repositioned fragments may be held in place by fracture interdigitation alone, it is best to provisionally hold them in place with 1.6-mm Kirschner wires (**Figure 17**) and follow with definitive fixation using subchondral miniscrews or bioabsorbable pegs.[23] The overlying posterior wall fragments are then reduced with a straight ball-spiked pusher, and the reduction is confirmed by direct visualization of the reduction on the retroacetabular surface (**Figure 18**). Each posterior wall fragment may then be fixed with a standard lag screw technique. Smaller fragments may require 2.4- or 2.7-mm screws. All screws placed close to the posterior rim must be confirmed to be extra-articular with C-arm visualization directly along the long axis of the screw or tangential to the screw[24] (**Figure 19**). This should be performed before buttress plate fixation, which may obscure radiographic visualization. Very small rim fragments may require the use of a spring plate. Because lag screws rarely can be inserted perpendicular to the fracture, excessive screw tightening will displace the wall fragments. The lag screws must be supplemented with a buttress plate that spans the posterior wall fragments from the ischium to the intact ilium. After plate application, the lag screws in the wall can be fully tightened.

Contouring of the buttress plate must be performed with great care. Slight undercontouring of the plate is preferred, which will result in compression of the posterior wall as the screws

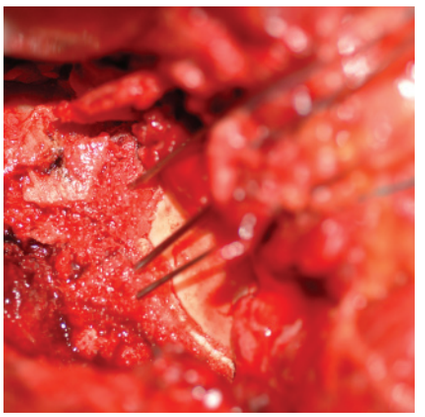

Figure 17 Intraoperative photograph after elevation and temporary Kirschner wire fixation of the impacted intra-articular fragments. The residual underlying cancellous bone defect has been filled with freeze-dried cancellous allograft bone. The Kirschner wires were subsequently exchanged for bioabsorbable pegs. (Copyright Berton R. Moed, MD, St. Louis, MO.)

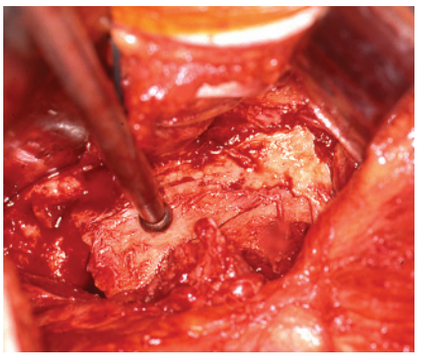

Figure 18 Intraoperative photograph showing the posterior wall fragments sequentially reduced and held with the straight ball-spiked pusher. Next, lag screws are inserted while the ball spike maintains the reduction, thus eliminating the need for temporary Kirschner wire fixation. The accuracy of the reduction of the articular surface is inferred from the reduction along the acetabular rim and that of the extra-articular cortical fracture lines. (Copyright Berton R. Moed, MD, St. Louis, MO.)

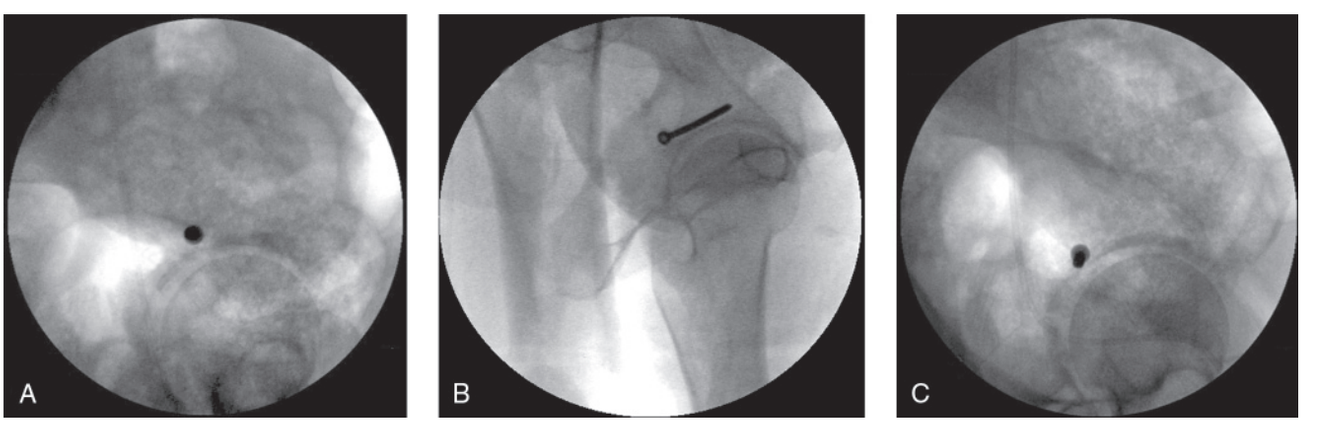

Figure 19 Examples of intraoperative fluoroscopic axial (**A**) and tangential (**B**) views showing extra-articular positioning of each lag screw after fixation of a posterior wall fragment. **C,** A screw shown to be compromising the articular surface—or too close to definitively be extra-articular—should be repositioned.

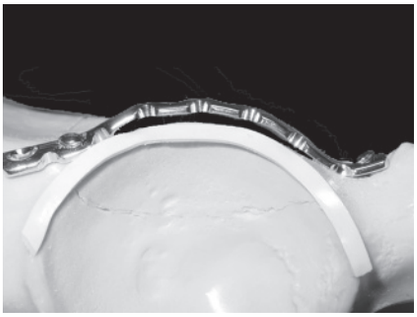

Figure 20 An inappropriately contoured plate loses contact with the posterior wall fragment and is unable to adequately buttress the fragment.

placed through the plate are tightened. However, an excessively undercontoured plate will crush the posterior wall or cause the wall fragments to displace and prevent the femoral head from fully seating within the acetabulum. An overcontoured plate will leave a gap between the posterior wall and the plate, resulting in a failure to buttress the fracture plus an attendant risk of loss of reduction (**Figure 20**). The buttress plate is best placed parallel and close to the rim of the acetabulum, where it can provide the most effective buttress for the wall fragments. A minimum of two screws above and two screws below the posterior wall fragments anchor the plate to the ilium and the ischium, respectively. Positioning the buttress plate too medially (away from the rim) provides poor stabilization of the posterior wall fragments and may result in loss of reduction (**Figure 21**). Plates that are not contoured parallel to the rim of the acetabulum and extend posterosuperiorly above the level of the top of the greater sciatic notch should be avoided. Placing screws into a plate in this location may put the superior gluteal nerve, artery, and vein at risk of excessive stretch or direct injury (**Figure 21**). Typically, a single, well-contoured buttress plate

Figure 21 Schematic image showing the approximate positions of the superior gluteal nerve (white line), artery (gray line) and vein (black line) are shown. Plates positioned above the angle of the greater sciatic notch may put the neurovascular bundle at risk for injury during screw insertion. Plates positioned too medial will not buttress the wall fragments.

is sufficient (**Figure 22**). However, in cases of multifragmented posterior wall fractures or those with extensive retroacetabular comminution, multiple plates may be required to buttress all of the critical fragments (**Figure 23**).

After plate application, intraoperative fluoroscopy allows the surgeon to confirm the reduction of the posterior wall by visualizing both the retroacetabular ilium and the congruity of the acetabular articular surface with the femoral head. The hip should be concentrically reduced on AP, obturator oblique, and iliac oblique fluoroscopic views (**Figure 23**). All screws should be confirmed to be in an extra-articular location and of appropriate length.

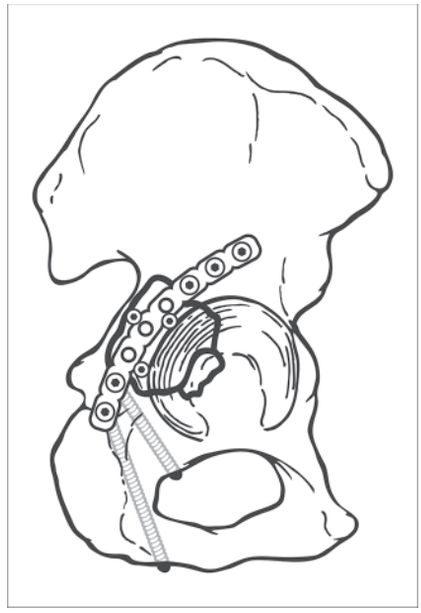

Figure 22 Illustration showing a typical posterior wall fixation construct. (Copyright Berton R. Moed, MD, St. Louis, MO.)

Evaluation and Treatment of Associated Injuries

Posterior wall fractures can occur in isolation. However, it takes substantial force to break the acetabulum, even in an elderly patient. As such, posterior wall fractures are often associated with other systemic injuries, and these patients should be evaluated as potentially multiply injured using standard Advanced Trauma Life Support protocols. In addition to systemic injuries, these patients often have localized associated injuries that directly affect fracture management.

As previously noted, posterior wall fractures usually result from an axial force along a flexed femur. Therefore, injuries to the ipsilateral knee or elsewhere along the line of applied force are common.[25] The exact nature and the incidence of these injuries are not well documented in the literature. Furthermore, these injuries often are occult.

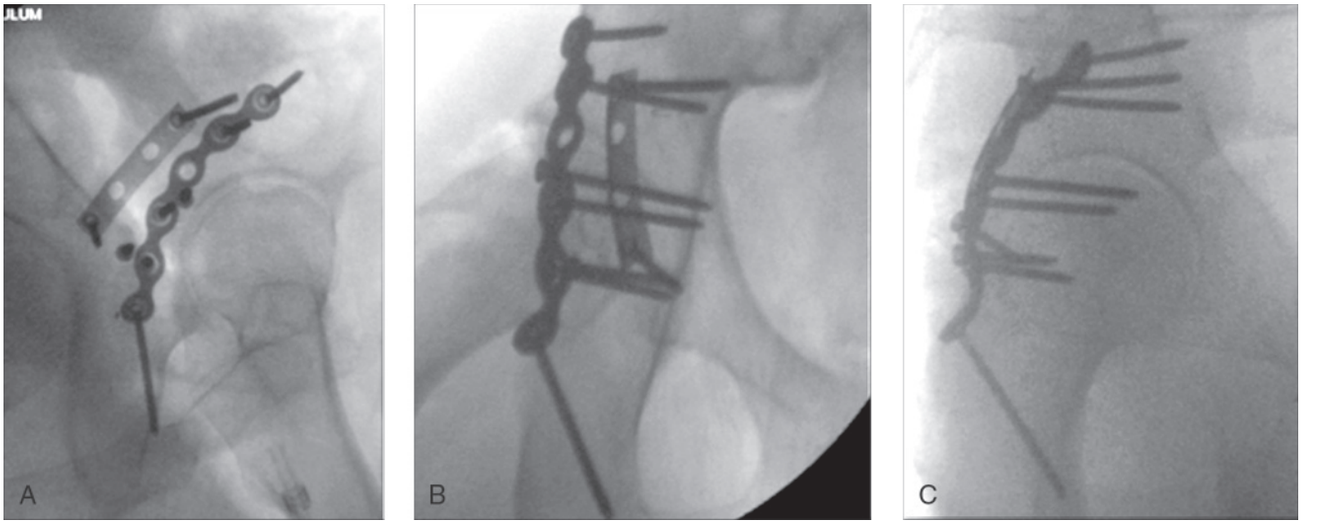

Figure 23 AP (**A**), obturator oblique (**B**), and iliac oblique (**C**) fluoroscopic views demonstrate the use of a supplemental plate, show congruency between the femoral head and the acetabulum, and document the appropriate location and length of the implants.

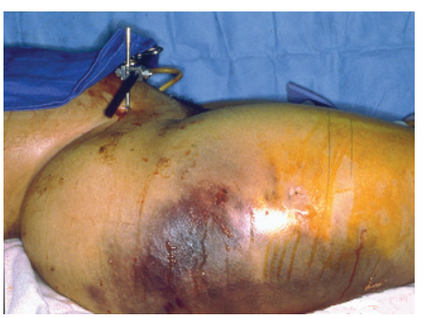

Figure 24 Clinical photograph of a Morel-Lavallee lesion in a patient with combined pelvic and acetabular fractures. (Copyright Berton R. Moed, MD, St. Louis, MO.)

Therefore, the knee must be carefully evaluated for instability, especially involving the posterior cruciate ligament. Often, this examination is difficult or limited because of patient discomfort.[26] Consequently, the knee should undergo a thorough examination with the patient under anesthesia at the conclusion of any required hip surgery. Ligamentous injuries are usually addressed at a later time; however, fractures of the patella often are repaired during the same anesthesia as the acetabular fracture surgery. To decrease tension on the sciatic nerve, the ipsilateral knee should be maintained in approximately 90° of flexion during acetabular fracture surgery. This knee position will stress the fixation of a newly repaired patellar fracture. Therefore, the acetabular fracture is usually addressed before fixation of the patellar fracture.

The Morel-Lavallee lesion (**Figure 24**) occurs when the skin and subcutaneous tissue are sheared from the underlying fascia over the trochanteric region. This closed, degloving, soft-tissue injury creates a potential space filled with hematoma and liquefied fat. It may be recognized by a fluid wave on palpation or later identified by the presence of a fluctuant, circumscribed area of cutaneous anesthesia and ecchymosis.

Morel-Lavallee lesions are more common with acetabular fractures resulting from lateral impact. However, these lesions can occur with a posterior wall fracture, and it is an important factor in surgical planning. Hak et al[27] found this fluid was culture-positive in 46% of the 24 patients, despite being a closed injury. In all cases, the lesions were débrided extensively either before or during surgery. An infection developed in three patients, but only one of these three had been culture-positive at the time of the initial débridement. Tseng and Tornetta[28] reported on a percutaneous method in a small number of patients, using a plastic brush and pulsed lavage to débride the injured adipose tissue. A closed-suction drain was placed within the lesion and then removed when the drainage was less than 30 mL during a 24-hour period. Fracture fixation was deferred until at least 24 hours after drain removal. Infections were avoided by using this technique.

Although both of these series were small, it is reasonable to assume that a surgical procedure through damaged tissue will increase the risk of wound problems and infection, and it appears that management should change depending on the severity of the lesion. For small lesions with little visible

damage to the skin, débridement and irrigation of the lesion should suffice as the first stage of acetabular fracture surgery before proceeding deep to the fascia. The incision for débridement should incorporate the vertical limb of the standard surgical approach. At the end of the procedure, wound closure can proceed normally, and what should be a relatively small and localized area of dead space can be managed with closed-suction drainage. For more severe lesions with an area of impaired skin, following the débridement as just described and after subsequent acetabular fracture fixation, the deep fascia should be closed, but the skin and subcutaneous tissue should be left open for wound management and secondary closure. With a severe lesion, débridement is performed as a separate procedure, and the acetabular surgery is delayed pending soft-tissue recovery.

Although associated injuries to major vessels are extremely rare, injury of the superior gluteal artery can occur. The injuring force is directed toward the superior gluteal artery, especially in the case of superior posterior wall fractures. The true incidence of this injury is unknown because the injured artery usually becomes occluded by clotted blood before surgical intervention. Nonetheless, bleeding from the superior gluteal artery will occasionally be encountered at the time of surgery. Whether the bleeding is the result of iatrogenic surgical damage or clot disruption in a previously injured vessel is immaterial. Whatever the cause, the bleeding can be substantial and must be quickly controlled. However, the surgeon should avoid direct clamping of the vessel. Attempts at direct clamping often are unsuccessful and usually cause damage to the superior gluteal nerve. Usually, direct packing of the injured vessel is all that is required. The packing should be left undisturbed for 20 to 30 minutes. In the rare instance in which the bleeding does not stop, it is best to close the wound and proceed with angiographic embolization.

In contradistinction to arterial injuries, associated nerve injuries are quite common. Traumatic injury of an ipsilateral peripheral nerve occurs in more than 10% of patients.[5,13] Nerve injury is usually caused by stretching related to the associated hip dislocation; however, direct laceration or crush of the sciatic nerve by displaced fracture fragments also can occur. Given the direction of the injuring force, the sciatic nerve is at greatest risk. Sciatic nerve injury is most common and is usually partial in nature, mainly involving the peroneal division. Therefore, it is important to carefully document the function of the sciatic nerve before surgery. The prognosis for functional recovery of a sciatic nerve injury is variable, depending on the degree of involvement of the peroneal division. Complete or nearly complete recovery of an injured tibial division can be expected; however, a severely injured peroneal division cannot be expected to recover good function.[29]

Other peripheral nerves, such as the femoral, obturator, and superior gluteal nerves, also may be injured. Gruson and Moed[30] documented 4 femoral nerve injuries in 726 acetabular fractures treated surgically. In two patients, the injury was caused by the trauma, and two injuries were iatrogenic. One of the traumatic nerve injuries was associated with a posterior wall fracture. At an average of 10 months, all patients had recovered grades 4 to 5 motor strength. The location of the superior gluteal nerve puts it at risk, and the obturator nerve also may be at risk. However, the muscles innervated by these nerves are difficult if not impossible to evaluate in the acute injury stage.

Approximately 7% of posterior dislocations of the hip have an associated fracture of the femoral head.[31] ORIF of both fractures is generally accepted as the best treatment option for a displaced acetabular fracture associated with a femoral head (Pipkin type IV) injury.[32] When the primary pathology is the femoral head fracture (the posterior wall fracture does not have surgical indications), the anterior Smith-Petersen approach is preferred.[32,33] Historical concerns of an increased risk of osteonecrosis of the femoral head by performing an anterior capsulotomy in the presence of a torn posterior capsule have been shown to be unfounded.[32,33] However, this anterior approach has been associated with an increased risk of heterotopic ossification.[32]

The presence of a posterior wall fracture with surgical indications mandates a posterior approach to fix the wall fracture. Although the Kocher-Langenbeck approach provides excellent visualization of the posterior wall, the intact femoral head blocks access to the femoral head fragments, which commonly originate from the anterior aspect of the head. One option is to perform two approaches: the anterior Smith-Petersen approach to address the head fracture followed by the Kocher-Langenbeck approach for the posterior wall.[32] A more recent and better option is to use a Ganz trochanteric flip osteotomy with surgical dislocation of the hip, as previously described.[19,34,35] This approach provides excellent visualization of the femoral head fragment and the posterior wall without any additive risk to the blood supply of the femoral head.[21,35]

When a femoral neck fracture occurs in association with a posterior wall fracture, the best approach is to consider the two fractures as separate entities, providing optimal treatment of each. The femoral neck in a young adult should be treated first in an urgent fashion, generally using a Watson-Jones approach.[25] The acetabular fracture can be addressed with a separate, posterior approach during the same anesthesia or at a later time, as the situation dictates. If planned in advance, the Watson-Jones approach can be placed so as not to compromise a subsequent Kocher-Langenbeck approach. However, if necessary, the inferior limb of the Watson-Jones approach can be incorporated into the Kocher-Langenbeck approach. This combination of injuries in an older adult is rare, and treatment is controversial; therefore, care must be individualized. However, addressing both injuries by performing THA as the primary treatment should be considered.[36]

In general, for fractures of the proximal femur associated with a posterior wall fracture of the acetabulum, both fractures are treated using the posterior approach.[25] A posterior wall fracture in association with an ipsilateral femoral shaft fracture is a relatively infrequent and challenging situation. Usually, these are high-energy injuries. There are multiple options for managing this combination of injuries, but stabilizing the femur is the main priority for general patient treatment. If the patient is stable and the surgeon is comfortable with the acetabular fracture surgery, both injuries can be managed during the same anesthesia. However, if the combined surgery may cause excessive physiologic stress to an already injured patient, or the surgeon is not comfortable with acetabular fracture surgery, it is best to stabilize the femur and leave the acetabulum for later reconstruction. If this is the situation and the hip is dislocated, closed hip reduction techniques are often unsuccessful or are not even possible. Rather than performing an open reduction of the dislocation, the hip can usually be reduced using a percutaneous technique.[37] Using fluoroscopy, a Schanz screw can be inserted into the proximal femoral fragment through a small stab wound. Using manual traction applied with a T-handle chuck applied to the end of the screw, the dislocation is reduced. The screw is then removed, the stab wound closed, and the limb maintained in traction until definitive surgery can be performed.

The gold standard for the treatment of a femoral shaft fracture is a reamed antegrade intramedullary nail. However, there is a concern that a Kocher-Langenbeck approach for acetabular fracture fixation in conjunction with antegrade nailing, either as a staged or a sequential procedure, will result in a higher complication rate than if an alternative method of femoral fracture fixation is selected.[25,38] This issue has not been well studied. However, in a small series of 13 patients, Bishop et al[38] reported that this approach was not associated with excessive rates of wound-healing complications, but the occurrence of heterotopic ossification increased. Therefore, retrograde nailing of the femoral shaft currently appears to be the better option.[25,39]

Outcomes and Postoperative Considerations

Important early complications consist of nerve injury, infection, injury to blood vessels, bleeding requiring transfusion, fracture malreduction, and implant malposition. Deep vein thrombosis can occur any time after the injury. Late complications include heterotopic ossification, osteonecrosis of the femoral head, traumatic hip joint arthritis, and patient dysfunction.

Early Complications

Letournel and Judet[5] reported a decreasing rate of iatrogenic nerve injury with increasing surgical experience. In the hands of surgeons experienced with acetabular fracture, iatrogenic nerve injury ranges from 1% to 3% in large series encompassing all acetabular fracture types.[5,40] In large series reporting on only fractures of the posterior wall, the rate was lower—less than 1%.[11,13,41] Intraoperative nerve monitoring has not been shown to improve on these already more than satisfactory results. Furthermore, a study showed that nerve monitoring is of questionable value for posterior wall fracture surgery, even when performed by less experienced surgeons.[42]

Injury to the gluteal nerves also may occur, especially if a Kocher-Langenbeck approach is used. The proximal extent of the approach through the gluteus maximus is to the first crossing nerve branch of the inferior gluteal nerve, which innervates the muscle (**Figure 25**). Traction in this area or further extension of the incision will denervate the anterosuperior portion of this muscle.[5,43] Excessive retraction of the gluteus minimus muscle and/or elevation near the greater sciatic notch can result in superior gluteal nerve dysfunction. Delay in the return of normal hip abductor muscle function has been reported after using the Kocher-Langenbeck approach.[44,45] Although the reasons for this dysfunction

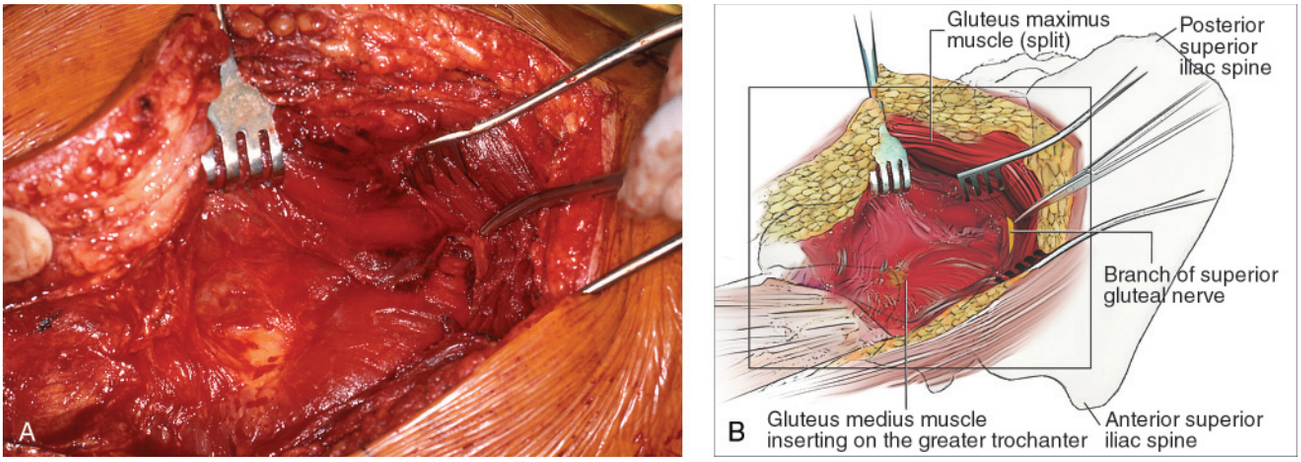

Figure 25 **A,** Intraoperative photograph showing the gluteus maximus muscle fibers split to the first nerve branch. A self-retaining retractor holds the gluteus maximus muscle fibers apart. The nerve (located at the tip of the scissors) is crossing the split in the gluteus maximus muscle fibers from posterior to anterior in the surgical field. (Copyright Berton R. Moed, MD, St. Louis, MO.) **B,** Companion drawing to clarify the exposure. (Reproduced with permission from Moed BR: Acetabular fractures: Kocher-Langenbeck approach, in Wiss DA, ed: *Master Techniques in Orthopaedic Surgery: Fractures*, ed 3. Philadelphia, PA, Lippincott Williams & Wilkins, 2012, pp 817-884.)

may be multifactorial, one possible explanation is iatrogenic injury to the superior gluteal nerve. As noted previously, iatrogenic traction injury to the femoral nerve is rare but does occur.[30] Recovery of nerve function can be expected.

Deep infection after posterior wall fracture surgery is uncommon, with reports ranging from zero to 1%.[4-6] However, deep infection is a devastating complication, resulting in joint destruction in up to 50% of patients.[5,11] Although surgeon experience will decrease the infection rate,[5] infection risk increases with increasing body mass index of the patient.[46,47] As noted previously, surgery through a compromised soft-tissue envelope (such as a Morel-Lavallee lesion) poses an increased infection risk. A high body mass index (≥ 30), intensive care unit stay, and the presence of a Morel-Lavallee lesion all have been shown to be independent risk factors for infection in acetabular fracture surgery.[46,48] It is uncommon for a patient with an isolated posterior wall fracture to require more than the equivalent of two units of blood during or after surgery.[11] If this occurs, other sources of bleeding should be sought. As previously noted, injury to the superior gluteal artery can occur, from either iatrogenic laceration or clot disruption. Early surgical treatment of posterior wall fractures is not associated with increased blood loss.[18]

The goal of posterior wall reconstruction is an anatomic restoration of the joint surface and a stable, congruent hip. In large case series, as judged by plain radiographs, anatomic reduction of posterior wall fractures has been reported in the range of 93.7% to 97.0%.[5,11,40] Despite the apparent anatomic reduction, there was no direct correlation with radiographic or clinical results. This situation could be caused by several associated factors, including cartilaginous injury to the acetabular or femoral joint surfaces. Another explanation is that plain radiographs are inadequate for evaluating articular reduction.[5,11] Moed et al[11,13] reported that two-dimensional CT is better at determining reduction after posterior wall fracture surgery, and residual irregularities at the articular surface can partially explain the differences between postoperative plain radiographic assessment and subsequent radiographic and clinical outcomes. The outcome of the joint is definitely at risk with an inadequate reduction (≥ 10-mm gap) or residual hip instability. Revision of posterior wall fractures is associated with fair to poor results in more than 50% of patients.[49,50]

Because of the anatomy of the retroacetabular surface, screws inserted along the acetabular rim and in certain positions on the retroacetabular surface place the joint surface at risk for intra-articular penetration. Although techniques for the safe placement of screws have been described, using intraoperative fluoroscopy, as described previously, is the best method.[5,24,51] Using postoperative, two-dimensional CT has no added benefit in this regard.[24] Furthermore, any information provided by postoperative CT would

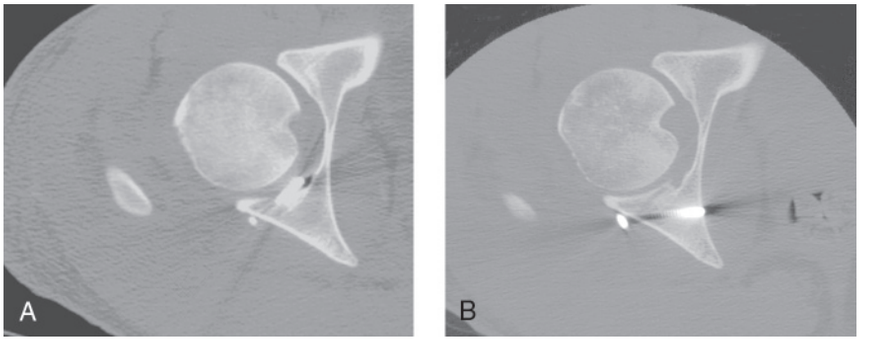

Figure 26 Postoperative CT can be used before the routine use of intraoperative fluoroscopy to assess screw position. Postoperative CT section after the fracture surgery showing intra-articular screw placement (**A**) and after revision surgery for screw repositioning (**B**). (Copyright Berton R. Moed, MD, St. Louis, MO.)

require revision surgery, whereas intraoperative fluoroscopy allows correction of the problem in real time, during the fracture fixation surgery (**Figure 26**).

Venous thromboembolism is a frequent complication in trauma patients. In acetabular fracture patients, the risk of deep vein thrombosis is high, and pulmonary embolism occurs in approximately 1% to 2% of patients.[5,52,53] Evidence-based clinical practice guidelines recommend routine perioperative chemical and/or mechanical prophylaxis.[54] However, for major orthopaedic surgery in patients not at increased risk for bleeding, such as a patient with an isolated posterior wall fracture, dual prophylaxis (chemical and mechanical) is indicated.[54] Mechanical prophylaxis using only portable, battery-powered units capable of recording and reporting proper wear time is recommended, and efforts should be made to ensure 18 hours of daily compliance.[54] To be effective, prophylaxis should continue for up to 35 days from the day of surgery.[54] Most acetabular fracture surgeons continue prophylaxis in some form until the patient is ambulatory. Despite the use of prophylactic treatment, the prevalence of posttraumatic and postoperative deep vein thrombosis occurs in approximately 11% to 15% of patients, with pulmonary embolism in approximately 1% of patients.[52,53] Fatal pulmonary embolism occurs in less than 0.5% of patients.[52,53]

Screening for deep vein thrombosis has not been found to be helpful.[52,53] Screening is indicated only in those patients who have received inadequate thromboprophylaxis.[53,54] Using an inferior vena cava filter for thromboprophylaxis is not recommended.[55] However, an inferior vena cava filter should be considered for therapeutic use in patients undergoing surgery in whom venous thromboembolism has been diagnosed preoperatively.[54] In a report of 88 patients with pelvic or acetabular fractures in whom deep vein thrombosis developed preoperatively and an inferior vena cava filter was placed, the complication rate was very low.[56] Postthrombotic syndrome developed in only one patient, and there were no recorded recurrent thromboemboli.[56]

Late Complications

The presence and the importance of heterotopic ossification is approach dependent. After a Kocher-Langenbeck approach, heterotopic ossification resulting in clinically significant loss of hip motion occurs in less than 10% of patients.[5,40] Several potential risk factors have been identified, such as male sex, patients with head injuries, and prolonged mechanical ventilation. Options for treatment include using perioperative prophylactic agents (for example, indomethacin and irradiation) and/or delayed excision of any heterotopic ossification causing clinical impairment.[57] The efficacy of indomethacin is subject to debate, and the advisability of using irradiation in a young population with less than 10% at risk is controversial. Therefore, for posterior wall fractures, delayed excision of any heterotopic ossification causing clinical impairment is perhaps the best treatment course.

The diagnosis of femoral head osteonecrosis after hip fracture-dislocation can be problematic. This entity must be distinguished from simple damage to the femoral head from the fracture trauma or mechanical wear from posterior wall fracture malreduction.[5,11,13] Experimental studies have shown that the blood supply to the femoral head during posterior hip dislocation is temporarily interrupted by stretching and twisting.[58] This may explain the fact that in posterior wall fractures, osteonecrosis of the femoral head is associated with prolonged dislocation, usually beyond 12 hours.[11,13,59] An intact obturator externus tendon may be protective of the femoral head blood supply when the hip is dislocated.[21,60] Osteonecrosis of the femoral head after posterior wall fracture surgery is associated with a poor

clinical outcome, usually requiring total joint arthroplasty.[5,11]

The best outcomes from the surgical treatment of posterior wall fractures are predicated on an anatomic reduction of the disrupted joint surface.[11,13] Letournel and Judet[5] reported clinical outcomes after acetabular fractures using the Merle d'Aubigné and Postel scoring system, which evaluates pain, ambulation, and range of motion. Matta[40] modified this system by scoring range of motion relative to the contralateral, uninjured hip. Many subsequent reports have used this modified scoring system, which evaluates clinical function of the injured hip. In 2002, Moed et al[11] reported 89% good to excellent clinical results at a mean follow-up of 5 years. These results are similar to the 82% reported by Letournel and Judet[5] and the 85% reported by Pantazopoulos et al.[61] Tannast et al[60] predicted a 70% survivorship of the hip joint at 20 years for posterior wall fractures of the acetabulum.

Overall patient functional outcomes after posterior wall fractures evaluated using the Musculoskeletal Function Assessment questionnaire have reported scores significantly worse than normative values.[62] Mobility and emotional categories were important determinants of the total score. In comparing the Musculoskeletal Function Assessment questionnaire to the modified Merle d'Aubigné scoring, the modified Merle d'Aubigné score revealed a ceiling effect, limiting its ability to show differences among patients with supposedly better clinical outcomes. The investigators concluded that although the modified Merle d'Aubigné score may be useful for evaluating isolated hip function in patients who have been treated for an acetabular fracture, its shortcomings limit its usefulness as a method for evaluating functional outcome in these patients.[62] It also has been shown that quality of life after acetabular fracture fixation continually improves during the 2-year postoperative period but remains lower than norms.[63] Anatomic reduction results in better quality-of-life outcomes in most dimensions.[63]

Summary

Restoring the congruity and the stability of the hip joint are the goals for treating a posterior wall fracture of the acetabulum. In general, a displaced fracture will need ORIF. Nonetheless, a substantial subset of fractures exist that can be successfully managed nonsurgically. However, a patient with a posterior wall fracture requires a complete evaluation, including a stress examination of the hip joint, before a nonsurgical course of treatment is selected. Although posterior wall fractures present problems unique from other acetabular fracture types, with attention to proper treatment principles, good to excellent clinical results can be obtained in most patients.

References

1. Knight RA, Smith H: Central fractures of the acetabulum. *J Bone Joint Surg Am* 1958;40(1):1-16.
2. Rowe CR, Lowell JD: Prognosis of fractures of the acetabulum. *J Bone Joint Surg Am* 1961;43:30-59.
3. Stewart MJ: Discussion: Prognosis of fractures of the acetabulum. *J Bone Joint Surg Am* 1961;43:59.
4. Stewart MJ, Milford LW: Fracture-dislocation of the hip: An end-result study. *J Bone Joint Surg Am* 1954;36(2):315-342.
5. Letournel E, Judet R: *Fractures of the Acetabulum*, ed 2. New York, NY, Springer-Verlag, 1993.
6. Templeman DC, Olson S, Moed BR, Duwelius P, Matta JM: Surgical treatment of acetabular fractures. *Instr Course Lect* 1999;48:481-496.
7. Moed BR, Dickson KF, Kregor PJ, Reilly MC, Vrahas MS: The surgical treatment of acetabular fractures. *Instr Course Lect* 2010;59:481-501.
8. Judet R, Judet J, Letournel E: Fractures of the acetabulum: Classification and surgical approaches for open reduction. Preliminary report. *J Bone Joint Surg Am* 1964;46:1615-1646.
9. Brooks RA, Ribbans WJ: Diagnosis and imaging studies of traumatic hip dislocations in the adult. *Clin Orthop Relat Res* 2000;377:15-23.
10. Marsh JL, Slongo TF, Agel J, et al: Fracture and dislocation classification compendium—2007: Orthopaedic Trauma Association classification, database and outcomes committee. *J Orthop Trauma* 2007;21(10, suppl):S1-S133.
11. Moed BR, Willson Carr SE, Watson JT: Results of operative treatment of fractures of the posterior wall of the acetabulum. *J Bone Joint Surg Am* 2002;84(5):752-758.
12. Baumgaertner MR: Fractures of the posterior wall of the acetabulum. *J Am Acad Orthop Surg* 1999;7(1):54-65.
13. Moed BR, Carr SE, Gruson KI, Watson JT, Craig JG: Computed tomographic assessment of fractures of the posterior wall of the acetabulum after operative treatment. *J Bone Joint Surg Am* 2003;85(3):512-522.
14. Moed BR, Ajibade DA, Israel H: Computed tomography as a predictor of hip stability status in posterior wall fractures of the acetabulum. *J Orthop Trauma* 2009;23(1):7-15.
15. Reagan JM, Moed BR: Can computed tomography predict hip stability in posterior wall acetabular fractures? *Clin Orthop Relat Res* 2011;469(7):2035-2041.
16. Davis AT, Moed BR: Can experts in acetabular fracture care determine hip stability after posterior wall fractures using plain radiographs and computed tomography? *J Orthop Trauma* 2013;27(10):587-591.
17. Grimshaw CS, Moed BR: Outcomes of posterior wall fractures of the acetabulum treated nonoperatively

after diagnostic screening with dynamic stress examination under anesthesia. *J Bone Joint Surg Am* 2010;92(17):2792-2800.

18. Furey AJ, Karp J, O'Toole RV: Does early fixation of posterior wall acetabular fractures lead to increased blood loss? *J Orthop Trauma* 2013;27(1):2-5.

19. Siebenrock KA, Gautier E, Ziran BH, Ganz R: Trochanteric flip osteotomy for cranial extension and muscle protection in acetabular fracture fixation using a Kocher-Langenbeck approach. *J Orthop Trauma* 1998;12(6):387-391.

20. Moed BR: The modified Gibson posterior surgical approach to the acetabulum. *J Orthop Trauma* 2010;24(5):315-322.

21. Gautier E, Ganz K, Krügel N, Gill T, Ganz R: Anatomy of the medial femoral circumflex artery and its surgical implications. *J Bone Joint Surg Br* 2000;82(5):679-683.

22. Moed BR, Willson Carr SE, Craig JG, Watson JT: Calcium sulfate used as bone graft substitute in acetabular fracture fixation. *Clin Orthop Relat Res* 2003;410:303-309.

23. Giannoudis PV, Tzioupis CC, Moed BR: Two-level reconstruction of comminuted posterior-wall fractures of the acetabulum. *J Bone Joint Surg Br* 2007;89(4):503-509.

24. Carmack DB, Moed BR, McCarroll K, Freccero D: Accuracy of detecting screw penetration of the acetabulum with intraoperative fluoroscopy and computed tomography. *J Bone Joint Surg Am* 2001;83(9):1370-1375.

25. Kregor PJ, Templeman D: Associated injuries complicating the management of acetabular fractures: Review and case studies. *Orthop Clin North Am* 2002;33(1):73-95.

26. Schmidt GL, Sciulli R, Altman GT: Knee injury in patients experiencing a high-energy traumatic ipsilateral hip dislocation. *J Bone Joint Surg Am* 2005;87(6):1200-1204.

27. Hak DJ, Olson SA, Matta JM: Diagnosis and management of closed internal degloving injuries associated with pelvic and acetabular fractures: The Morel-Lavallée lesion. *J Trauma* 1997;42(6):1046-1051.

28. Tseng S, Tornetta P III: Percutaneous management of Morel-Lavallee lesions. *J Bone Joint Surg Am* 2006;88(1):92-96.

29. Fassler PR, Swiontkowski MF, Kilroy AW, Routt ML Jr: Injury of the sciatic nerve associated with acetabular fracture. *J Bone Joint Surg Am* 1993;75(8):1157-1166.

30. Gruson KI, Moed BR: Injury of the femoral nerve associated with acetabular fracture. *J Bone Joint Surg Am* 2003;85(3):428-431.

31. Brumback RJ, Kenzora JE, Levitt LE, Burgess AR, Poka A: Fractures of the femoral head. *Hip* 1987:181-206.

32. Swiontkowski MF, Thorpe M, Seiler JG, Hansen ST: Operative management of displaced femoral head fractures: Case-matched comparison of anterior versus posterior approaches for Pipkin I and Pipkin II fractures. *J Orthop Trauma* 1992;6(4):437-442.

33. Stannard JP, Harris HW, Volgas DA, Alonso JE: Functional outcome of patients with femoral head fractures associated with hip dislocations. *Clin Orthop Relat Res* 2000;377:44-56.

34. Gardner MJ, Suk M, Pearle A, Buly RL, Helfet DL, Lorich DG: Surgical dislocation of the hip for fractures of the femoral head. *J Orthop Trauma* 2005;19(5):334-342.

35. Siebenrock KA, Gautier E, Woo AK, Ganz R: Surgical dislocation of the femoral head for joint debridement and accurate reduction of fractures of the acetabulum. *J Orthop Trauma* 2002;16(8):543-552.

36. Ward AJ, Chesser TJ: The role of acute total hip arthroplasty in the treatment of acetabular fractures. *Injury* 2010;41(8):777-779.

37. Kuhn KM, Boudreau JA, Watson JT: Rare combination of ipsilateral acetabular fracture-dislocation and pertrochanteric fracture. *Am J Orthop (Belle Mead NJ)* 2013;42(8):372-375.

38. Bishop JA, Cross WW III, Krieg JC, Chip Routt ML Jr: Antegrade femoral nailing in acetabular fractures requiring a Kocher-Langenbeck approach. *Orthopedics* 2013;36(9):e1159-e1164.

39. Moed BR, Watson JT: Retrograde nailing of the femoral shaft. *J Am Acad Orthop Surg* 1999;7(4):209-216.

40. Matta JM: Fractures of the acetabulum: Accuracy of reduction and clinical results in patients managed operatively within three weeks after the injury. *J Bone Joint Surg Am* 1996;78(11):1632-1645.

41. Gänsslen A, Steinke B, Krettek C: Internal fixation of acetabular posterior wall fractures. *Oper Orthop Traumatol* 2009;21(3):283-295.

42. Baumgaertner MR, Wegner D, Booke J: SSEP monitoring during pelvic and acetabular fracture surgery. *J Orthop Trauma* 1994;8(2):127-133.

43. Moed BR: Acetabular fractures: Kocher-Langenbeck approach, in Wiss DA, ed: *Master Techniques in Orthopaedic Surgery: Fractures*, ed 3. Philadelphia, PA, Lippincott Williams & Wilkins, 2012, pp 817-868.

44. Dickinson WH, Duwelius PJ, Colville MR: Muscle strength testing following surgery for acetabular fractures. *J Orthop Trauma* 1993;7(1):39-46.

45. Matta JM, Olson SA: Factors related to hip muscle weakness following fixation of acetabular fractures. *Orthopedics* 2000;23(3):231-235.

46. Karunakar MA, Shah SN, Jerabek S: Body mass index as a predictor of complications after operative treatment of acetabular fractures. *J Bone Joint Surg Am* 2005;87(7):1498-1502.

47. Porter SE, Russell GV, Dews RC, Qin Z, Woodall J Jr, Graves ML: Complications of acetabular fracture surgery in morbidly obese patients. *J Orthop Trauma* 2008;22(9):589-594.

48. Suzuki T, Morgan SJ, Smith WR, Stahel PF, Gillani SA, Hak DJ: Postoperative surgical site infection following acetabular fracture fixation. *Injury* 2010;41(4):396-399.

49. Mayo KA, Letournel E, Matta JM, Mast JW, Johnson EE, Martimbeau CL: Surgical revision of malreduced acetabular fractures. *Clin Orthop Relat Res* 1994;305:47-52.

50. Dean DB, Moed BR: Late salvage of failed open reduction and internal fixation of posterior wall fractures of the acetabulum. *J Orthop Trauma* 2009;23(3):180-185.

51. Norris BL, Hahn DH, Bosse MJ, Kellam JF, Sims SH: Intraoperative

fluoroscopy to evaluate fracture reduction and hardware placement during acetabular surgery. *J Orthop Trauma* 1999;13(6):414-417.

52. Borer DS, Starr AJ, Reinert CM, et al: The effect of screening for deep vein thrombosis on the prevalence of pulmonary embolism in patients with fractures of the pelvis or acetabulum: A review of 973 patients. *J Orthop Trauma* 2005;19(2):92-95.

53. Moed BR, Miller JR, Tabaie SA: Sequential duplex ultrasound screening for proximal deep venous thrombosis in asymptomatic patients with acetabular and pelvic fractures treated operatively. *J Trauma Acute Care Surg* 2012;72(2):443-447.

54. Guyatt GH, Akl EA, Crowther M, Gutterman DD, Schuünemann HJ; American College of Chest Physicians Antithrombotic Therapy and Prevention of Thrombosis Panel: Executive summary: Antithrombotic therapy and prevention of thrombosis, 9th ed. American College of Chest Physicians evidence-based clinical practice guidelines. *Chest* 2012;141(2, suppl):7S-47S.

55. Falck-Ytter Y, Francis CW, Johanson NA, et al: Prevention of VTE in orthopedic surgery patients: Antithrombotic therapy and prevention of thrombosis, 9th ed. American College of Chest Physicians evidence-based clinical practice guidelines. *Chest* 2012;141(2, suppl):e278S-e325S. Medline

56. Toro JB, Gardner MJ, Hierholzer C, et al: Long-term consequences of pelvic trauma patients with thromboembolic disease treated with inferior vena caval filters. *J Trauma* 2008;65(1):25-29.

57. Moed BR, Israel H: Heterotopic ossification prevention and treatment: What is the best way to prevent heterotopic ossification following acetabular fracture fixation? in Wright JG, ed: *Evidence-based Orthopaedics*. Philadelphia, PA, Saunders Elsevier, 2009, pp 353-359.

58. Yue JJ, Wilber JH, Lipuma JP, et al: Posterior hip dislocations: A cadaveric angiographic study. *J Orthop Trauma* 1996;10(7):447-454.

59. Aho AJ, Isberg UK, Katevuo VK: Acetabular posterior wall fracture: 38 cases followed for 5 years. *Acta Orthop Scand* 1986;57(2):101-105.

60. Tannast M, Pleus F, Bonel H, Galloway H, Siebenrock KA, Anderson SE: Magnetic resonance imaging in traumatic posterior hip dislocation. *J Orthop Trauma* 2010;24(12):723-731.

61. Pantazopoulos T, Nicolopoulos CS, Babis GC, Theodoropoulos T: Surgical treatment of acetabular posterior wall fractures. *Injury* 1993;24(5):319-323.

62. Moed BR, McMichael JC: Outcomes of posterior wall fractures of the acetabulum. *J Bone Joint Surg Am* 2007;89(6):1170-1176.

63. Borg T, Berg P, Larsson S: Quality of life after operative fixation of displaced acetabular fractures. *J Orthop Trauma* 2012;26(8):445-450.